

## Garciniamangostana Linn. Pericarp Extract Reduced Malondialdehyde (MDA) Level in Cigarette Smoke Exposed Rats

Nabel Ahmed A Mansour<sup>1</sup>, Aulani'am<sup>2</sup>, Joni Kusnadi<sup>1</sup>

<sup>1</sup>Department of Food Science and Technology, Faculty of Agriculture Technology, Brawijaya University, Jl. Veteran, Malang, East Java, Indonesia 65145.

<sup>2</sup>Laboratory of biochemistry, Department of chemistry, Faculty of sciences, Brawijaya University, Jl. Veteran, Malang, East Java, Indonesia 65145

**Abstract:-** Crude extract of mangosteen (*GarciniaMangostana* L) pericarp (CEMP) possess many biological and pharmacological activities. The aim of this study is to analyse the effect of CEMP consumption for 3 weeks on lipid peroxidation as shown by malondialdehyde (MDA) level in cigarette smoke exposed rats. Twenty five Wistar male rats were randomly divided into five groups, i.e.: a normal control group, an exposed cigarette control group and three treatment groups. The treatment groups either received 200; 400; and 600 mg CEMP/kg body weight (BW), respectively. The diets in the form of pellets were freely consumed (ad libitum) and were given for three weeks. Rats were exposed to cigarette smoke one time per day. Blood samples were taken on the last day for MDA analyses. The MDA level statically analysis by ANOVA test and following by post Hoc test .After 3 weeks treatment, the mean MDA levels between groups were significantly differences (P=0.000). On day 21<sup>th</sup>, the MDA levels of control group , exposure by cigarette smoke group and groups that supplemented with 0; 200; 400 and 600 mg CEMP / kg BW were  $0.126 \pm 0.02$ ;  $0.637 \pm 0.04$ ;  $0.423 \pm 0.03$ ;  $0.235 \pm 0.03$  and  $0.136 \pm 0.03$   $\mu\text{g/mL}$ , respectively. It is also interesting to point out the decrease of the lung morphological damage by CEMP treatment. These results indicate the beneficial effect of CEMP in the MDA level reducing on the rats that exposed by cigarette.

**Keywords:-** crude extract of mangosteen pericarp (CEMP), cigarette, malondialdehyde (MDA), lipid peroxidation, rat.

### I. INTRODUCTION

Smoking caused many dangerous diseases like lung cancer, tumors and others. Cigarette smoke contains more than 4000 elements and at least 200 of them are harmful to health. The main toxins in cigarettes are tar, nicotine, and carbon monoxide. In addition, cigarette smoke also contains other chemicals that are not less toxic such as ammonia, formic acid, formaldehyde, hydrogen cyanide, etc. (Ruslan, 1996). The combustion of cigarettes can lead to the production of reactive oxygen species (ROS). Free radicals, components of ROS are found in cigarette mainstream and side stream smoke. Side stream Cigarette smoke contains more toxic gases and free radicals than the mainstream cigarette smoke (Church and Pryor, 1985). The adverse effects of smoking may result from the accumulation of oxidative damage brought about by ROS, which is called oxidative stress (Avogbe, et al. 2005).

To prevent further impact of cigarette smoke on health, the provision of intake of antioxidant compounds can be an effective therapeutic alternative for smokers. According to Halliwell and Gutteridge (1992), antioxidants can act as a catcher (scavenger) so that the free radical chain oxidation reaction can be interrupted. One of the antioxidant is mangosteen pericarp extract. Crude ethanol extract of mangosteen pericarp (CEMP) contains high concentration of antioxidants. The main natural antioxidants in CEMP are polyphenols, and one of the polyphenols is the flavonoid.

### II. METHODS

This study was conducted in a completely randomized post-test only design that compared five groups of rats. The treatments were P0 (normal control), P1 (cigarette smoke exposed (CE) ), P2 (CE + 200 mg / kg weighing of rat), P3 (CE + 400 mg / kg weighing of rat) and P4 (CE + 600 mg / kg weighing of rat). The experiment was carried out for three weeks in an animal house at the Laboratory of Animal physiology, Department of Biology, Faculty of Sciences, Brawijaya University, Malang, Indonesia.

#### 2.1 Crude ethanol extract from mangosteen pericarp (CEMP)

The whole pericarps (outer and inner peels) of *G. mangostana* were harvested from Malang, East Java, Indonesia. The samples were first cleaned to remove any residual compost and washed thoroughly to remove

impurities. After washing, the samples were chopped into small pieces ( $0.5 \times 1.0 \text{ cm}^2$ ) and dried over a night in a tray dryer at  $45^\circ\text{C}$ . Then chopped samples were ground with a grinder to make powder (around 18 mesh). All ground samples were placed in  $70^\circ\text{C}$  distilled water for 15 min at the ratio of sample powder : water of 1:4. The mixtures were boiled 4 times or until no content of tannin was found by dropping 2% gelatin solution in the mixtures (Weecharangsan et al. 2006). The mixtures were filtrated, the residues were then dried at  $40 - 45^\circ\text{C}$  in the hot air oven. The dried powder was macerated at room temperature for 7 days with 50% ethanol. The crude extract were filtered and evaporated at  $40 - 45^\circ\text{C}$  in the hot air oven to obtain the dried crude extracts. The obtained extracts were stored in a cage containing dry silica gel prior using in each experiment.

## 2.2 Animals and diet preparation

Twenty five male Wistar rats with average body weight of 180 - 200 g were used in this experiment. These rats were divided into five groups (P0, P1, P2, P3 and P4) that consisted of 5 rats each. These rats were kept in a plastic cage in a temperature-controlled room ( $22 \pm 2^\circ\text{C}$ ) under a light/dark cycle of 12 h. Groups P1, P2, P3 and P4 were exposed by cigarette for 4 weeks. Once the production of reactive oxygen species (ROS) was reached, the rats received CEMP treatment. Group P2, P3 and P4 received CEMP (200, 400 and 600 mg/ kg BW ) by gastric intubations every day during 3 weeks together with exposed cigarette. Control CE animals (P1) are exposed cigarette without CEMP. And control normal animals (P0) are no exposed by cigarette and without CEMP. Blood was collected by intra vena of rats tail after treatment by CEMP. Blood was centrifuged for 15 min at 3500 rpm. Plasma was used to determination of MDA levels. At the end of the experimental period, the rats were killed by decapitation. The lung was removed and rinsed with physiological saline and was stored at  $-80^\circ\text{C}$  until be analysed.

## 2.3 Malondialdehyde(MDA) measurements

Measurement of MDA level was done according to the method of Soewoto et al. (2001) in brief: the blood were collected , and centrifuged at 1500 rpm for 15 minutes and followed by serum collection. The serum was added to 0.75 mL of 0.67% TCA solution, and the mixture was then placed into a boiling-water containing water bath for 10 minutes. After it was cold, it was read using a spectrophotometer at a wavelength of 532 nm to determine the MDA concentration.

## 2.4 Histopathological analysis of black hole pulmonary in the lung of rats

The lung were collected in 4% formalin for preparing the section slide of lung. The sections were stained with hematoxylin and eosin for histologic examination. Images of 10 fields for each lung section were captured randomly at x40 magnification. Each image was then analyzed using AxioVision (Zeiss, Germany). Alcian blue (AB)-periodic acid-Schiff (PAS) staining was used to examine goblet cell hyperplasia. Images of 3 fields for epithelium in cartilaginous bronchus were captured randomly at x100 magnification (Chan et al. 2009).

## 2.5 Data Analysis

Results of MDA are expressed as mean  $\pm$  standard error of the mean (S.E.M) and for histopathological by descriptive. To determine the effect of CEMP on the MDA levels, data were analysed by one way analysis of variance (ANOVA) using the general linier model procedure of SPSS 16.0 software. Significant differences between dietary treatments were analysed by Post-Hoc Tukey.  $P < 0.05$  values were considered as significantly different.

## III. RESULTS

The result of MDA levels after treatment in all five groups were significantly different ( $P=0.000$ ) (Table 1). On day 21th , the MDA level of P0, P1, P2, P3, and P4 were  $0.126 \pm 0.02$ ;  $0.637 \pm 0.04$ ;  $0.423 \pm 0.03$ ;  $0.235 \pm 0.03$  and  $0.136 \pm 0.03 \mu\text{g/mL}$ , respectively. The MDA levels in P1 group were the highest, and MDA levels in P0 were the lowest. The results showed CEMP can reduce the MDA level. The dose CEMP 600 mg/ kg BW of rats were not significantly difference with normal rat. It is indicated that CEMP can used as candidate therapeutic of rats that exposed by cigarette smoke, by reducing MDA production as free radicals.

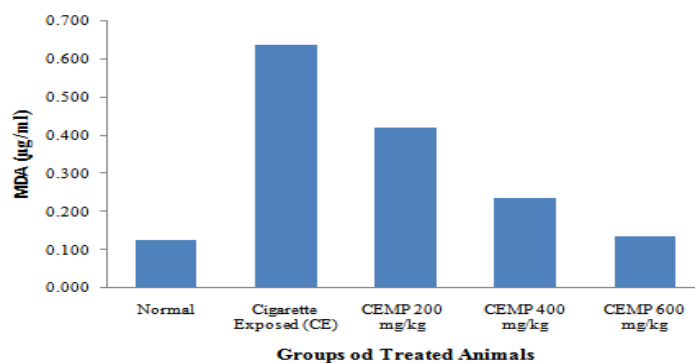


Figure 1. Malonaldehyde (MDA) levels of all treated rat groups.

Table 1. MDA levels in all treated rats.

Treatment	MDA (µg/ml)
Normal (P0)	0.126 a
Cigarette exposed (CE) (P1)	0.637 d
Cigarette + 200 mg/kg MPE (P2)	0.423 c
Cigarette + 400 mg/kg MPE (P3)	0.235 b
Cigarette + 600 mg/kg MPE (P4)	0.136 a

\*difference word showed the differences in one column, using Post Hoc Tukey ( $\alpha = 0.05$ ).

The histological examination of the lung of negative control group showed normal structure of the lung (Fig. 2). Lung section of the positive control is remarkable changes, differences versus negative control (Fig. 3). When CEMP was given administrated in rats, some morphological changes was regarded (Fig. 4, 5, and 6).

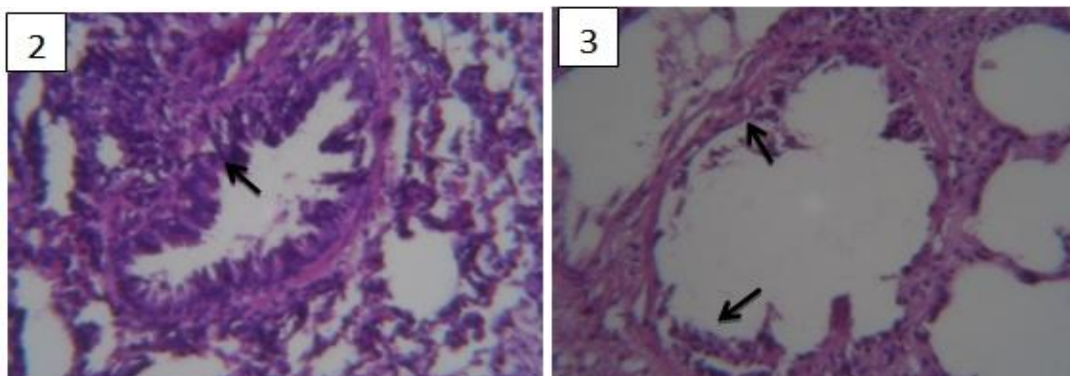


Fig. 2: Photomicrograph of the lung of control rat showing normal architecture of lung cell.

Fig. 3: Photomicrograph of the lung of exposure cigarette rat showing thinner lung cell.

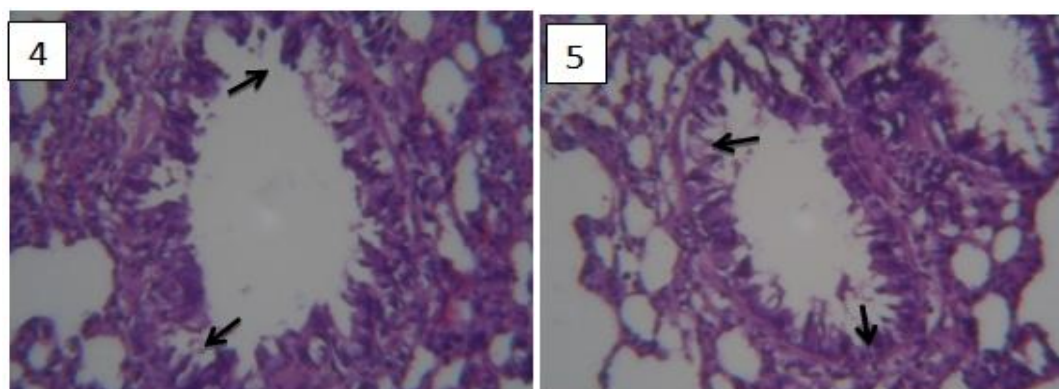


Fig. 4: Photomicrograph of the lung of 200 mg/kg CEMP treated rat showing the illustration improvement of lung cell.

Fig. 5: Photomicrograph of the lung of 400 mg/kg CEMP treated rat showing the illustration improvement of lung cell.

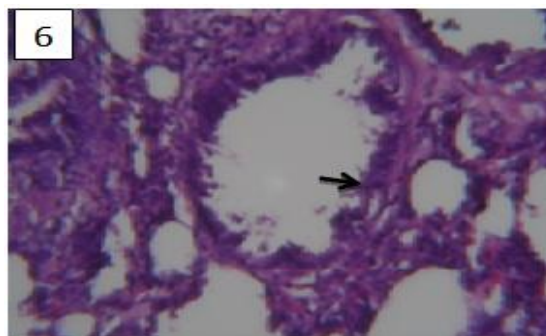


Fig. 6: Photomicrograph of the lung of 600 mg/kg CEMP treated rat showing the illustration improvement of lung cell.

#### IV. DISCUSSION

The MDA levels after treatment in all five groups were significantly different ( $P=0.000$ ) as shown in Table 1. Increasing levels of MDA that showed the lipid peroxidation process in the four groups were due to the exposure of various chemical substances containing cigarette smoke that included free radicals (Ueta et al. 2003). In this study, rats were exposed to passive cigarette smoke. Cigarette smoke directly inhaled by active smokers is called mainstream smoke is the smoke generated from burning cigarettes. The side stream smoke contains toxic gases and free radicals compared to the main smoke. This cigarette smoke can cause lipid peroxidation.

In order to explain lowering-MDA level by CEMP consider to its richness in antioxidant capacity to counteract free radicals. The antioxidant activities of extract of *G. mangostana* pericarp evaluated by DPPH method was 5.94  $\mu\text{g/ml}$  (Palakawong et al. 2010). The higher concentration of CEMP, the lower was the lipid peroxidation level.

In this study, the CEMP consumption in 200 mg/kg BW of rat (P2), 400 mg/kg BW of rat (P3), and 600 mg/kg BW of rat (P4) noticeable effect could be obtained compared with control group. The study by Kaplan *et al.* (2002) in which pomegranate juice containing 0.175 mg flavonoids/day given to atherosclerotic mice was able to decrease macrophage lipid peroxidation. In another study, consumption of pomegranate juice that contained 0.035 mg flavonoids could reduce oxidative stress in atherosclerotic rats (Aviram et al. 2000). This difference is probably due to the exposure to cigarette smoke that led to higher oxidative stress conditions; so the intake of flavonoids have to be higher to be able to suppress the occurrence of lipid peroxidation. Flavonoids in CEMP contribute to counteract the free radicals in several ways. Some flavonoids work by inhibiting an enzyme that is responsible for the production of superoxide anions such as xantin oxidase. Moreover, it can also act as a scavenger of free radicals by donating electrons to superoxide radicals or lipid radicals to be stable (Smith et al. 2005).

The results of histopathologicallung analysis demonstrated that cigarette smoke caused airspace enlargement. In our study, airspace enlargement increasing was observed after cigarette exposure without supplemented CEMP (Fig. 3) compared with normal control (Fig.2), in agreement with Lee *et al.*(2005) who also found that exposure of Sprague-Dawley rats to cigarette smoke caused a 74% increase in airspace enlargementafter longer exposure. In contrast, Stevenson et al. (2007) did not show airspace enlargement until 8 months after cigarette exposure. The difference is likely due to the age of rat for the time of cigarette exposure. The airspace enlargements were smaller than CE control in the groups that supplemented with CEMP (Fig. 4, 5 and 6). The higher doses of CEMP,are the smaller airspace enlargements of the rat lung. It indicated that CEMP can protect the lung morphology after 3 weeks treatment. The precise mechanisms of the protective role of CEMP against CE-induced lung injury are currently unclear. CEMP contains of high antioxidant activity that to considered can improve the rat lung. In Chinese green tea model, antioxidant arrest multiple harmful mechanism of lung injury through protection of cells and tissues from oxidative damage by scavenging oxygen-free radicals generated from cigarette exposed (Klauning et al. 1999).

This research showed that the content of natural antioxidants in CEMP can counteract oxidative stress due to exposure to cigarette smoke. The limitation in our study are necessary to determine the type of antioxidants that most responsible for the results and difficult to discern in an in vivo study the cause and effect relationship between the beneficial effect of CEMP on lung structural damage. In conclusion, giving CEMP at the levels of 200, 400, and 600 mg/ kg BWof rats could suppres the occurrence of lipid peroxidation as indicated by MDA levels.

#### Acknowledgments

We would like to thank the Biochemistry Laboratory Team, Brawijaya University, Malang, Indonesia for kinds support to work my theme research.

## REFERENCES

- [1]. Aviram M, Dornfeld L, Rosenblat M, Volkova N, Kaplan M, Coleman R, Hayek T, Presser D, and Fuhrman. Pomegranate juice consumption reduces oxidative stress, atherogenic modifications to LDL, and platelet aggregation: studies in humans and in atherosclerotic apolipoprotein E-deficient mice. *Am J Clin Nutr*. 2000;71:1062-76.
- [2]. Avogbe PH, Ayi-Fanou L, Autrup H, Loft S, Fayomi B, Sanni A. Ultrafine particulate matter and high-level benzene urban air pollution in relation to oxidative DNA damage. *Carcinogenesis* 2005; 26:613-20.
- [3]. Chan KH, Ho SP, Yeung SC, So WHL, Cho C, KKoo MWL, Lam WK, Ip MSM, Man RYK and Mak JCW. 2009. Chinese green tea ameliorates lung injury in cigarette smoke-exposed rats. *Respiratory Medicine*, 2009. V 103, n. 11, p. 1746 – 1754.
- [4]. Church DF, Pryor WA. Free-radical chemistry of cigarette 3.smoke and its toxicological implications. *Environ Health Perspect*. 1985; 64:111-26.
- [5]. Halliwell B, Gutteridge JMC. Free radical in biology and medicine. 4th ed. New York: Oxford; 2007.
- [6]. Kaplan M, Hayek T, Raz A, Coleman R, Dornfeld L, Vaya J. Pomegranate juice supplementation to atherosclerotic mice reduces macrophage lipid peroxidation, cellular cholesterol accumulation and development of atherosclerosis. *J Nutr*.2001; 131:2082-89.
- [7]. Klaunig JE, Xu Y, Han C, et al.The effect of tea consumption on oxidative stress in smokers and nonsmokers.*Proc Soc Exp Biol Med* 1999; 220: 249-254.
- [8]. Lee JH, Lee DS, Kim EK, Choe KH, Oh YM, Shim TS, Kim SE, Lee YS, and Lee SD. Simvastatin inhibits cigarette smoking-induced emphysema and pulmonary hypertension in rat lungs. *Am J Respir Crit Care Med* 2005; 172:987-993.
- [9]. Palakawong c, Sophanodora P, Pisuchpen S and Phongpaichit S. Antioxidant and antimicrobial activities of crude extracts from mangosteen (*Garciniamangostana L.*) parts and some essential oils. *International Food research Journal* (2010) 17: 583 – 589.
- [10]. Ruslan G. Efek Merokok terhadap Rongga Mulut. *Cermin Dunia Kedokteran* 1996; 113:11-20. Indonesian.
- [11]. Smith C, Marks AD, Lieberman M. Basic medical biochemistry a clinical approach. 2nd ed. Philadelphia: Lippincott William & Wilkins; 2005.
- [12]. Stevenson CS, Docx C, Webster R, et al. Comprehensive gene expression profiling of rat lung reveals distinct acute and chronic responses to cigarette smoke inhalation. *Am J Physiol Lung Cell Mol Physiol* 2007; 293:L1183-1193.
- [13]. Ueta E, Tadokoro Y, Yamamoto T, Yamane C, Suzuki E, Nanba E. The effect of cigarette smoke exposure and ascorbic acid intake on gene expression of antioxidant enzymes and other related enzymes in the livers and lungs of Shionogi rats with osteogenic disorders. *Toxicol Sci*. 2003; 73:339-47.
- [14]. Weecharangsan, W., Opanasopit, P., Sukma, M., Ngawhirunpat, T., Sotanaphun, U., Siripong, P., 2006. Antioxidative and neuroprotective activities of extracts from the fruit hull of mangosteen (*Garciniamangostana Linn.*). *Med. Princ. Pract.* 15, 281-287.